

# Hypertrichosis Not Uncommon After Laser Removal of Facial Hair

ARTICLES BY  
MITCHEL L. ZOLER  
Philadelphia Bureau

GRAPEVINE, TEX. — Facial-hair removal with laser energy can backfire and trigger hypertrichosis if the regimen is not optimized, Dr. Andrea Willey said at the annual meeting of the American Society for Laser Medicine and Surgery.

In a review of more than 500 women who underwent photoepilation, it was found that paradoxical hair stimulation occurred in about 10%, much more common than previously reported.

A reliable way to prevent this outcome is to cool the surrounding skin with ice packs during laser treatment, along with using the maximum tolerated laser fluence and employing a double-pass technique, said Dr. Willey, who is a dermatologist at Oregon Health and Science University, Portland.

She and her associates reviewed before and after photos of 543 women who were treated for facial hair at a laser center in Spain from December 1998 to December 2003. The women were aged 16-52 years; 68% had type III skin, and the remaining women had either type II or type IV skin.

About 80% were treated with an alexandrite laser, whereas the others were treated with either an Nd:YAG

laser or intense pulsed light. They received 3-23 treatments.

At follow-up, an average of 10% of the women had increased facial hair, 8% had no change, 78% had reduced hair growth, and 3% had complete hair removal. The remaining 1% had incomplete information and weren't included in the analysis.

Women with hypertrichosis after treatment had the extra hair predominantly in their beard area. All of the affected women had prominent vellus hair before treatment, noted Dr. Willey.

No apparent link between skin type and hair growth was found. Of the 57 women with hair growth, 16 had polycystic ovary syndrome or irregular menses.

The cause of paradoxical hypertrichosis in this setting is not clear, and several mechanisms probably play a role, she said.

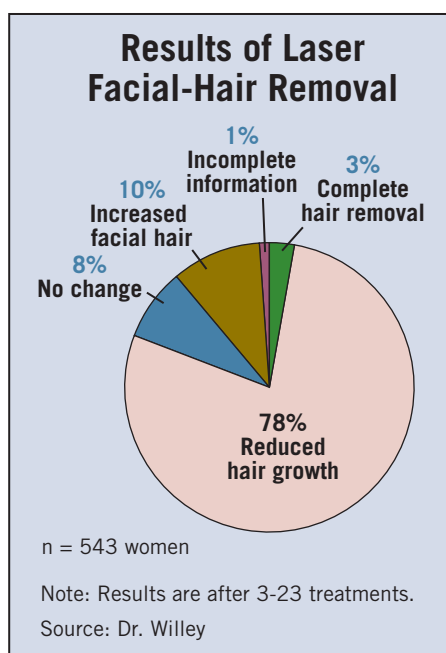
One possibility is that subtherapeutic laser energy injures hair follicles, thus stimulating growth rather than killing the follicles. To prevent this, dermatologists in Spain began to use ice packs, high fluence, and a double-pass technique.

Since this method started in late 2003, there have been no additional cases of paradoxical hypertrichosis in any patients treated with this approach, Dr. Willey said.

Several dermatologists who heard the report at the meeting said that their own anecdotal experience confirmed Dr. Willey's report.

"You can predict which women will have this. They all have fine, almost downy hair on dark skin that is type III or higher," said Dr. Jeffrey S. Dover, a dermatologist in private practice in Chestnut Hill, Mass.

"I don't treat thin, wispy hairs on the neck because the likelihood of hypertrichosis is so high," added Dr. E. Victor Ross, director of the laser and cosmetic dermatology unit at Scripps Clinic in San Diego. ■



## For Hidradenitis Suppurativa, Hair Removal Aids Tx

GRAPEVINE, TEX. — Hair removal by intense pulsed light is a useful adjunctive treatment for refractory hidradenitis suppurativa, based on experience with 10 patients at one center.

Five of the treated patients had clear improvement in their clinical status after 3-4 hair-removal treatments, with reduced or resolved lesions in the treated area. The remaining five patients had improvement after four to eight treatments, Dr. Agneta Troilius said at the annual meeting of the American Society of Lasers in Medicine and Surgery. The treatment also resulted in less scarring than usually occurs when hidradenitis suppurativa (HS) lesions resolve.

"Hair removal is one element of treatment" for a disease that affects as many as 4% of women, said Dr. Troilius, head of the laser and vascular anomaly section of the department of dermatology at Lund University in Malmö, Sweden.

The series included women aged 21-45 years with skin type II or III who had active HS for several years and had lesions that had affected their social lives.

Treatment was with an intense pulsed light (IPL) device, the Ellipse model made by Danish Dermatologic Development, using the hair applicator to deliver 645- to 950-nm light. Treatment was with a fluence of 17-19 J/cm<sup>2</sup>, delivered as 20- to 40-microsecond pulses with a 1.5-microsecond delay. Treatments were at 1-month intervals. For pain control, treated areas were pretreated with a eutectic mixture of lidocaine and prilocaine (EMLA), and also were treated with contact cooling.

"One drawback to this treatment is that it is painful to treat in the affected areas," Dr. Troilius said. Treatment of HS may be further refined by combining hair removal with photodynamic therapy or anti-inflammatory therapy with newly available biological drugs. ■

## Low-Energy Laser for Pseudofolliculitis Barbae Reduces Pain

GRAPEVINE, TEX. — Reduced laser energy can be effective and more acceptable to patients who are being treated for pseudofolliculitis barbae, based on results from a study with 11 evaluable patients.

"Lower fluences offer hair modulation without permanent hair reduction," Dr. Rafael A. Schulze said at the annual meeting of the American Society for Laser Medicine and Surgery.

The hair follicles become smaller and weaker, and less prone to cause pseudofolliculitis barbae. Lower laser fluences also mean less conductive heating and therefore less pain. Treatment with lower energy, at less than half the power usually used for hair removal, also means that the laser device can be smaller and potentially more portable, said Dr. Schulze, a dermatologist at Brooke Army Medical Center, Fort Sam Houston, Tex.

Pseudofolliculitis barbae, caused by the curling and growth of hair follicles into adjacent skin, occurs primarily in African Americans and causes inflammatory papules and pustules. It can also cause skin discoloration, hypertrophic or keloidal scarring, and secondary infections. Standard treatments include topical steroids, chemical depilatories, electrolysis, and laser hair reduction.

Standard laser hair reduction is done with a high-fluence device, usually at a dose of 22-40 J/cm<sup>2</sup>, which delivers a total power of 940 watts at an energy level of 24 J/cm<sup>2</sup>. This approach is painful in patients with darker skin and can cause pigmentation changes, scarring, or blistering. The laser device needed to deliver this energy is large and expensive, and at least two or three

treatments are usually needed, at 4- to 6-week intervals. This treatment is designed to permanently destroy hair follicles.

Dr. Schulze and his associates examined the efficacy and safety of treatment with a 1064-nm Nd:YAG StarLux laser that delivered 12 J/cm<sup>2</sup> with a 10-mm spot size and 20-millisecond pulses, producing a total power dose of 390 watts.

The Lux handpiece contained a water-cooled sapphire window; no topical anesthesia was used.

The treatment was designed not to destroy hair follicles but to cause a slight insult in them and make the hairs weaker and smaller, said Dr. Schulze, who had no financial conflicts to disclose for this study.

The study enrolled 21 men and 1 woman with pseudofolliculitis barbae and skin type IV-VI who were scheduled to receive weekly low-fluence laser treatments for 5 weeks, followed by 4 weeks of follow-up. Their age range was 21-42 years, with an average of 24. The participants were told to continue whatever grooming methods they had used before laser treatment, including clipping their facial hair and using a chemical depilatory.

Photographs of the necks of each patient were assessed before and after treatment by a panel of 10 dermatologists, who scored the outcomes based on papule counts, dyspigmentation, cobblestone appearance, and global assessment. Thirteen of the 22 patients completed the study. Two of the 13 completers failed to follow the protocol and changed their grooming method during the

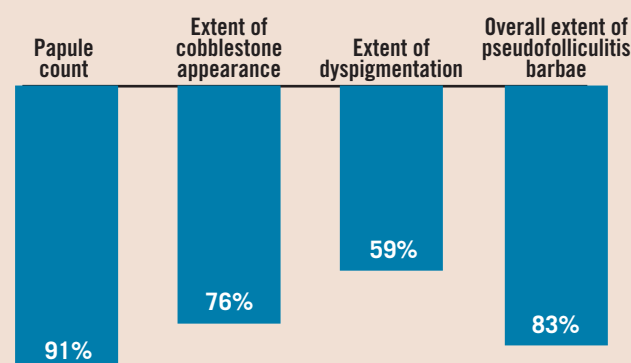
study, so they were excluded from the final analysis.

Among the 11 evaluable patients, none developed pigmentation changes, crusting, blistering, or scarring.

The global efficacy assessment showed an average 83% improvement for the composite of papule number, dyspigmentation, and cobblestone appearance, a statistically significant difference, compared with baseline.

Each of the individual assessments was also significantly improved at follow-up, compared with baselines. (See box.) ■

### Average Reductions From Baseline With Low-Fluence Laser Treatment



Note: Data based on a study of 11 patients who each received five treatments for pseudofolliculitis barbae.  
Source: Dr. Schulze